

# Histopathological analysis of unilateral condylar hyperplasia: difficulties in diagnosis and characterization of the disease

**B. Vásquez<sup>1</sup>, S. Olate<sup>2</sup>, M. Cantín<sup>3,4</sup>,  
 C. Sandoval<sup>3,5</sup>, R. Fariña<sup>6</sup>,  
 M.del Sol<sup>5</sup>**

<sup>1</sup>Universidad de Tarapacá, Arica, Chile; <sup>2</sup>Division of Oral and Maxillofacial Surgery, Universidad de La Frontera, Temuco, Chile; <sup>3</sup>Facultad de Odontología, Universidad de La Frontera, Temuco, Chile; <sup>4</sup>Centre for Biomedical Research, Universidad Autónoma de Chile, Temuco, Chile; <sup>5</sup>PhD Program in Morphology, Universidad Autónoma de Chile, Temuco, Chile; <sup>6</sup>Department of Oral and Maxillofacial Surgery, Universidad de Chile, Santiago, Chile

*B. Vásquez, S. Olate, M. Cantín, C. Sandoval, R. Fariña, M. del Sol: Histopathological analysis of unilateral condylar hyperplasia: difficulties in diagnosis and characterization of the disease. Int. J. Oral Maxillofac. Surg.* 2015; xxx: xxx–xxx.  
 © 2015 International Association of Oral and Maxillofacial Surgeons. Published by Elsevier Ltd. All rights reserved.

**Abstract.** The aim of this study was to perform a histological analysis of the conditions in patients undergoing surgery for unilateral condylar hyperplasia (UCH) using different histopathological analytical techniques and to describe the complications and existing controversy in order to better define the disease. A partial condylectomy was performed in five patients who had been diagnosed with UCH using clinical and imaging methods. The samples obtained were analyzed using routine histological techniques including haematoxylin–eosin, Van Gieson, picrosirius, alcian blue/haematoxylin–eosin, and AgNOR staining. The analyses were performed by an observer who was blinded to the clinical parameters of the disease. The cellularity, tissue layers, size of the anatomical structures, and the relationships between them were assessed. The analysis of these patients was complemented by a review of the scientific literature. Variability was observed in the analysis of the cases. The presence of connective tissue was detected at the bone level, with cartilage formation at different levels. Each island presented levels of involvement that could indicate various degrees of aggressiveness. Type I collagen was observed in most cases, although type III was also identified. The development of histological diagnostic methods to determine the aggressiveness or level of involvement in UCH is not currently possible. Further studies are needed to establish new histological classifications.

**Key words:** condylar hyperplasia; facial asymmetry; condylectomy.

Accepted for publication 27 November 2015

Hyperplasia is defined as the growth of the number of cells present in a certain tissue with no increase in their size. When this affects the mandibular condylar head, it is called condylar hyperplasia (CH) and is

characterized by alterations in both the condylar and facial morphology.<sup>1</sup>

Classifications have been developed in an attempt to standardize the concept of CH and its treatment,<sup>2</sup> establishing a series

of parameters associated with its clinical presentation and the conditions of diagnosis and treatment. Classification systems related to the clinical presentation, imaging characteristics, and functional aspects

have also been proposed.<sup>3</sup> The classification proposed by Slootweg and Müller includes limited histological aspects within the parameters<sup>4</sup>; they established that different degrees of invasion of fibrocartilage islands are associated with the degree of aggressiveness of CH, classifying this from level 1 to 4.

Saridin et al.<sup>5</sup> recently performed a histopathological study of unilateral condylar hyperplasia (UCH) using the classification proposed by Slootweg and Müller.<sup>4</sup> They reported that the identification of the four condylar layers at the histological level using haematoxylin–eosin is complex, and only two layers were used (the four initial ones were condensed) in order to identify them with greater clarity. The patterns described by Slootweg and Müller,<sup>4</sup> Saridin et al.,<sup>5</sup> Eslami et al.,<sup>6</sup> and Villanueva-Alcojol et al.<sup>7</sup> have not varied significantly in their histological descriptions. On the other hand, diagnosis assisted by histology, single photon emission computed tomography (SPECT), and clinical conditions has been reported.<sup>8</sup>

Wurgaft and Montenegro have stated that ascertaining the growth mechanism of the mandibular condyle at the tissue level is useful in achieving a good diagnosis and in implementing an appropriate treatment protocol that respects and guides tissue development.<sup>9</sup> The aim of this study was to perform a histological analysis of a case series of five patients with CH type 1B (UCH) and to determine its characteristics using different histopathological analytical techniques. A discussion of the histological diagnosis in relation to that reported in the international literature is also presented.

## Materials and methods

A descriptive study of a series of cases was performed. This research was conducted in the division of oral and maxillofacial surgery and the centre for morphological and surgical studies of the study institution in Temuco, Chile. The study was approved by the research ethics committee of the study university and was performed in accordance with the ethical guidelines established in the Declaration of Helsinki. All of the patients agreed to participate in the study.

## Diagnosis and surgical procedure

Five patients aged between 15 and 18 years (three female and two male), who underwent a high or proportional condylectomy following a diagnosis of UCH (CH 1B<sup>2</sup>) were included in the study.

The methodology for diagnosing and treating the subjects has been reported previously and followed the sequence described by Olate et al.<sup>10</sup>; clinical studies including facial and dental analyses, cone beam computed tomography (CBCT) for the analysis of the condyles, and SPECT<sup>11</sup> were used to diagnose the progressive facial asymmetry associated with active UCH. Clinically, the patients presented a chin deviation greater than 5 mm towards the contralateral side, with a posterior crossbite and an absence of joint pain symptoms. Only in one case did the maxilla present a maxillary cant of 2 mm. The gonion of the hyperplastic side was lower than on the contralateral side in all of the subjects.

Partial resection of the condylar head was performed under general anaesthesia by the same surgeon using a pre-auricular or endaural approach and a condylar head osteotomy, which was conducted using an ultrasound system (Piezotome 2; Satelec Acteon, Acteon Group, Paris, France). All patients underwent subsequent orthodontic treatment. Some were enrolled for treatment with orthognathic surgery, while others were treated exclusively with corrective orthodontics.

## Histological study

The resected hyperplastic condyles were fixed immediately in 10% buffered formalin for 48 h, decalcified in 10% ethylenediaminetetraacetic acid (EDTA) buffer solution for a period of 2 months, dehydrated in a series of increasing alcohol concentrations, and embedded in paraffin (Histosec; Merck Millipore, Darmstadt, Germany). Sections 3 µm thick were obtained from the blocks using a Microm HM355S rotary microtome (Microm International, Walldorf, Germany). These were stained with haematoxylin–eosin, Van Gieson, picrosirius, and alcian blue (pH 2.5)/haematoxylin–eosin, as well as undergoing staining of the argyrophilic nucleolar organizer region (AgNOR) to observe argentaffin proteins. The slides were viewed under a Leica microscope and photographed with a Leica ICC50 HD camera (Leica Microsystems, Heerbrugg, Switzerland). The presence, extension, and characteristics of the tissue layers comprising the condylar surface were assessed according to the description by Wurgaft and Montenegro.<sup>9</sup>

The analyses were performed by an observer who was blinded to the clinical parameters of the disease.

## Results

The histological analysis showed differences in condylar architecture (Table 1). In the area of greatest pressure, all of the condyles presented a well-defined surface and proliferative and fibrocartilaginous layers. However, the extension and thickness varied across the condylar surface. Clinically, the only patient who presented maxillary involvement in the facial asymmetry was case 3; the others exclusively showed facial asymmetry with chin deviation and a unilateral posterior crossbite (contralateral to the hyperplastic condyle).

### Case 1

In this patient, the right side was compromised (Fig. 1). The surface layer was observed to be larger in the superior area of the condyle compared to the lateral areas (Fig. 2A). The cellular component was present, and type I collagenous fibres were arranged parallel to the articular surface in the outer area and, to a lesser extent, in all directions in the deepest area (Fig. 2B).

The surface layer was also thicker in the central area of the condyle, with abundant cellularity (Fig. 2A) and a transition towards the not very well-defined fibrocartilaginous layer. A small number of collagenous fibres were observed and picrosirius staining revealed these to be mainly type I (Fig. 2B).

In the fibrocartilage layer, hyperactivity was detected in the zone of probably the greatest compression, with some interruptions in the bone plate and penetration of hypertrophic chondroblastic cells towards the medullary bone component of the mandibular condyle (Fig. 2A). Cartilage islands were observed in the trabeculae of the medullary bone with a positive reaction for alcian blue pH 2.5 and with surrounding osteoblastic activity (Fig. 2C).

Silver staining revealed many AgNOR points scattered throughout the nuclei of the cells of the proliferative layer and of the chondrocytes of the fibrocartilaginous layer that were in the outermost area (Fig. 2D). The hyperplastic chondrocytes showed a minor presence of AgNOR points. Some chondrocytes with AgNOR points were observed at the trabecular level of the medullary bone of the condyle.

### Case 2

In this patient, the left side was involved (Fig. 3). The proliferative layer was thicker, probably in the area of greatest pressure. It showed abundant cellularity

Table 1. Distribution and histological characteristics of patients with unilateral condylar hyperplasia.

Case	Age (years)	Sex	Affected side	Number of layers of the articular surface	Compact bone tissue	Picrosirius polarization staining method	Cartilage islands <sup>a</sup>	Alcian blue pH 2.5 <sup>a</sup>	AgNOR <sup>a</sup>
1	15	Male	R	4	Present, discontinuous	Abundant type I collagen was observed in all layers of the articular surface and in the compact and spongy bone; type III collagen was observed mainly in the fibrocartilage layer and trabecular bone	+++	++	+++
2	18	Female	L	3 <sup>b</sup>	Absent	Type I collagen was distributed mainly in the surface layer and trabecular bone; type III collagen was present in greater amounts in the interface of the proliferative and fibrocartilaginous layers	+++	+	+++
3	17	Female	L	4	Present, discontinuous	Type I collagen was found in all layers of the articular surface in different proportions; type III collagen was present in greater amounts in the surface layer and trabecular bone	+	+	++
4	17	Male	R	4	Present, discontinuous	Type I collagen was distributed in large amounts throughout the condylar structure; type III collagen was observed mainly in the thick surface layer and in greater amounts in the proliferative layer	±	–	+
5	16	Female	R	4	Present, discontinuous	Type I collagen was observed mainly in the fibrocartilage layer and trabecular bone furthest from the articular surface; type III collagen was observed mainly on the surface and proliferative layers and the outermost bone trabeculae	+	–	+

R, right; L, left.

<sup>a</sup>Negative '–'; very scarce '±'; scarce '+'; regular '++'; abundant '+++'.  
<sup>b</sup>Absence of calcified cartilage layer.

with undifferentiated mesenchymal cells on the surface and small, flattened chondrocytes with nuclei parallel to the surface, whereas deep down they appeared larger and rounded (Fig. 4A). Type I collagenous fibres were observed in very small numbers, scattered mainly parallel to the surface (Fig. 4B).

The fibrocartilage layer appeared rather like hyaline cartilage, with greater thickness in the area of greatest pressure and presenting an abundant number of hyperplastic chondrocytes. Medullary spaces of cancellous bone were in direct contact with the overlying cartilage (Fig. 4A). The type I collagenous fibres were perpendicular to the surface (Fig. 4C).

AgNOR points were observed in the nuclei of the cells of the proliferative and cartilaginous layers; nevertheless, in the latter the silver staining was observed mainly in the most superficial chondrocytes. Only some chondrocytes presented AgNOR points. There were also some chondrocytes with AgNOR points in the medullary bone trabeculae (Fig. 4D).

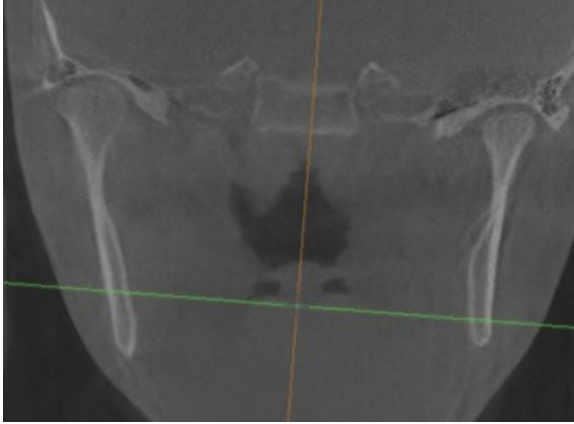
### Case 3

The condyle in this patient had four well-defined layers across the condylar surface (Fig. 5A). The surface layer was thickest in the central area of the condyle, with organized type I collagenous fibres paral-

lel to the surface and in all directions in the deepest area (Fig. 5B, C). Type III collagenous fibres appeared in smaller quantities (Fig. 5B). Of note, some chondrocytes were observed on the surface area of this layer (Fig. 5C).

The proliferative layer displayed abundant cellularity and scant extracellular matrix; this differentiated it easily from the underlying fibrocartilaginous layer, which was constituted of chondrocytes immersed in an extracellular matrix rich in type I collagenous fibres scattered in different directions.

The layer of calcified cartilage made it easy to differentiate the connective tissue that covers the condyle from the condylar

4 *Vásquez et al.*

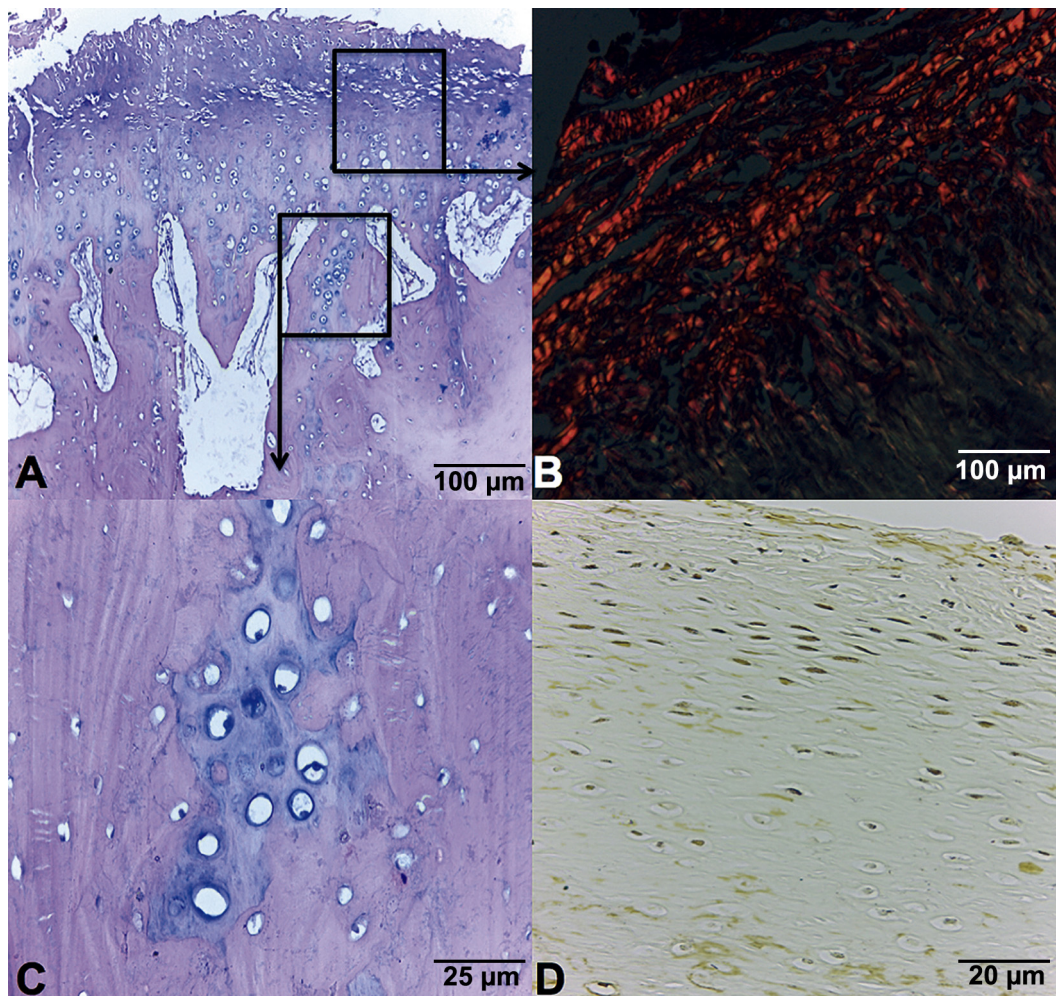
*Fig. 1.* Patient 1: right mandibular condyle of a larger size than the left side. SPECT confirmed the presence of bone activity.

bone tissue; the latter comprised mature compact lamellar bone tissue. Silver staining showed AgNOR points in the nuclei of the cells of the proliferative and fibrocartilaginous layers (*Fig. 5D*).

#### Case 4

In this case, the layers were continuous and varied in thickness according to the area in which they were found, being thicker in the central area (*Fig. 6A*). The surface layer appeared thicker. Type I collagenous fibres were dispersed in groups parallel to the articular surface and in multiple directions in the deepest area (*Fig. 6B*).

The proliferative layer presented abundant cellularity and scarce extracellular matrix, which was easily differentiated from the underlying layer. The



*Fig. 2.* Condylar hyperplasia. (A) Photomicrograph showing the condylar tissues. Proceeding from top to bottom, one sees the articular, proliferative, fibrocartilage, and calcified cartilage layers, respectively (haematoxylin–eosin and alcian blue stain; bar = 100 µm). (B) Type I collagen fibres arranged parallel to the articular surface and in all directions in the deeper area (picosirius stain; bar = 100 µm). (C) Cartilage islands present within the bony trabeculae (haematoxylin–eosin and alcian blue stain; bar = 25 µm). (D) Nucleolar reaction was observed in abundance in cells of the proliferative layer and chondrocytes of the fibrocartilaginous layer located in the outermost area, while this was less intense in hyperplastic chondrocytes in the deepest area and bone calcified layer (AgNOR stain; bar = 20 µm).

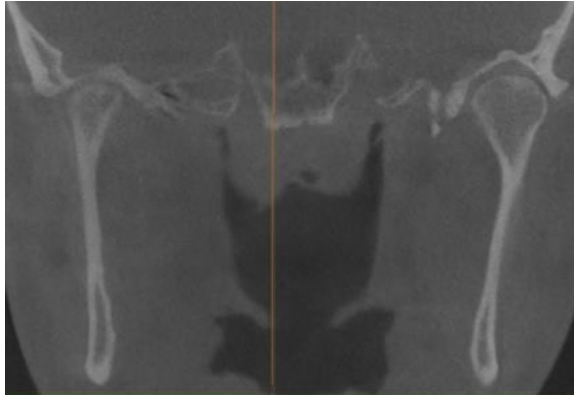


Fig. 3. Patient 2: left mandibular condyle showing unilateral condylar hyperplasia.

fibrocartilaginous layer comprised chondrocytes immersed in an abundant extracellular matrix rich in type I collagenous fibres scattered in several directions. In comparison with the surface layer, this layer was not as thick and had few hyperplastic chondrocytes (Fig. 6A).

The layer of calcified cartilage was evident and related to the mature compact

bone tissue of the mandibular condyle in the deep area.

#### Case 5

In this patient, the right side was involved, with a classical clinical presentation of unilateral crossbite and chin deviation (Fig. 7). As in cases 3 and 4, all the layers

on the surface of this condyle were well delimited, with greater thickness in the central region. Picosirius staining showed an irregular distribution of collagenous fibres, revealing type I (red) and type III (green) fibres (Fig. 6C). The cellular component comprised some fibrocytes, and chondrocytes were present, isolated or in small groups, distributed mainly across the surface of this layer.

The layer of calcified cartilage rested on a mature continuous bone plate with lamellae and osteons. The remains of cartilage were observed in the cancellous bone, but less than had been observed in the first two cases.

A small number of cells with AgNOR points were observed on the proliferative and fibrocartilaginous layers and chondrocytes located on the surface layer (Fig. 6D).

#### Discussion

The aetiology of CH remains unclear.<sup>2</sup> It has been suggested that trauma, environmental, and genetic alterations may have

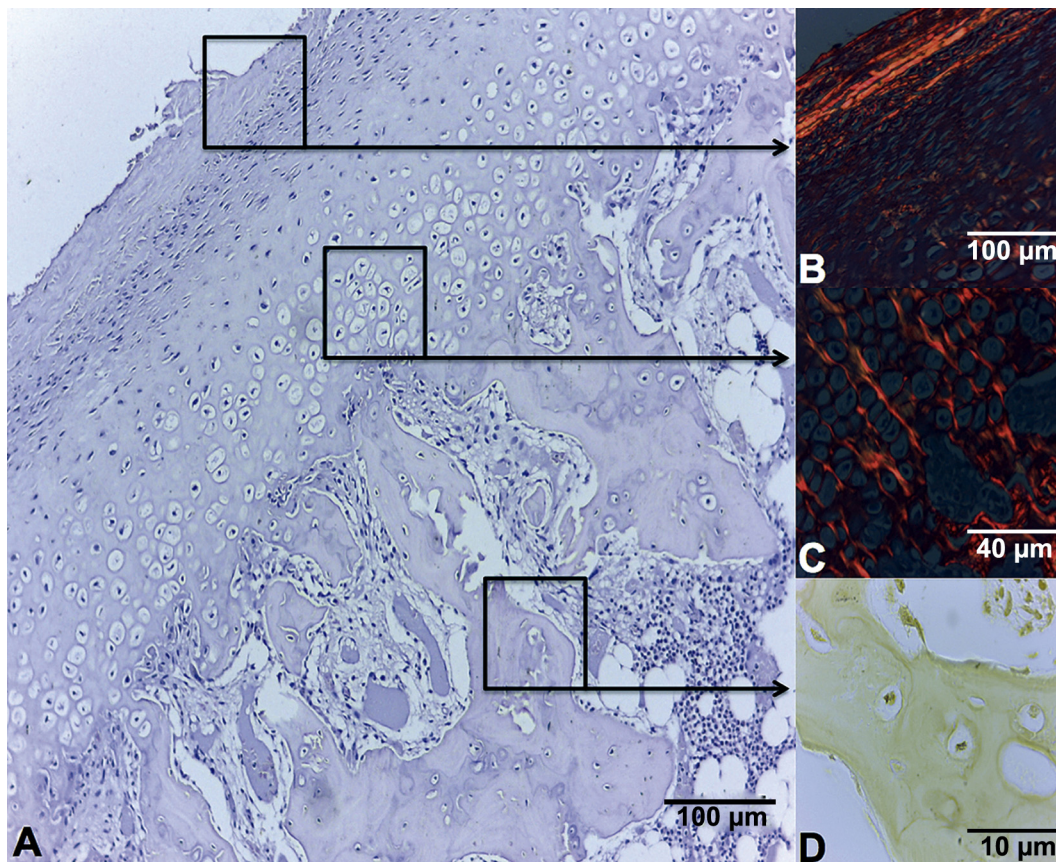
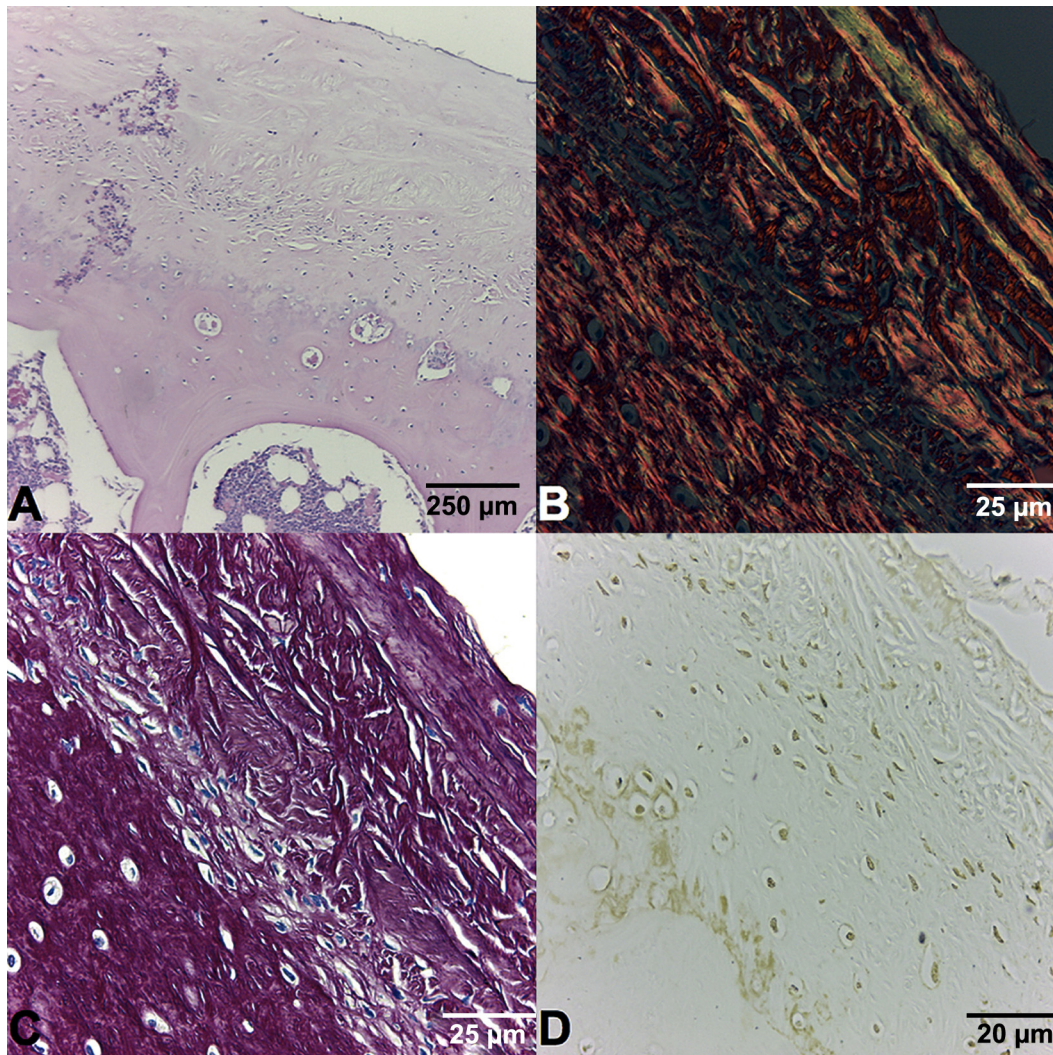


Fig. 4. Condylar hyperplasia. (A) Photomicrograph showing the condylar tissues. The proliferative layer is thicker, with undifferentiated mesenchymal cells in the surface region, and has a high number of chondrocytes. The fibrocartilage layer appears rather as hyaline cartilage, with many hyperplastic chondrocytes and scarce extracellular matrix (haematoxylin-eosin and alcian blue stain; bar = 100 µm). (B) Scarce type I collagen fibres parallel to the surface in the proliferative layer, and (C) arranged perpendicular to the surface in the fibrocartilage layer (picrosirius stain; bar = 40 µm). (D) Nucleolar reaction in chondrocytes of the medullary bone trabeculae (AgNOR stain; bar = 20 µm).



*Fig. 5.* Condylar hyperplasia. (A) Condyle presenting its four distinct layers and scarce cartilage (haematoxylin–eosin stain; bar = 250 µm). (B) Type III collagen fibres arranged parallel to the surface and in all directions in the deepest area (van Gieson stain; bar = 25 µm). (C) The presence of chondrocytes was observed even in the surface region (picosirius stain; bar = 25 µm). (D) Nucleolar reaction was seen in the proliferative cells and fibrocartilage layer (AgNOR stain; bar = 20 µm).

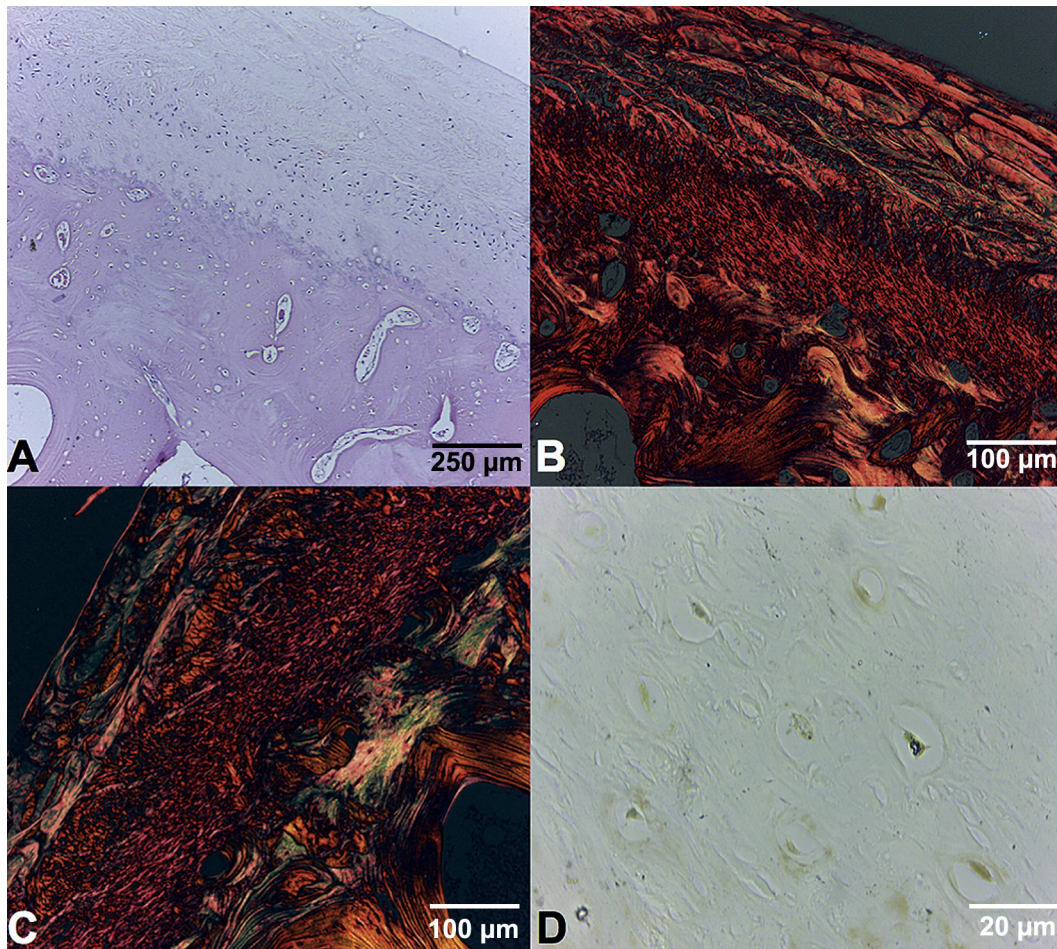
some relevance. Nevertheless, an important association with the patient's sex has been established, with a greater prevalence in female subjects,<sup>12</sup> possibly indicating a certain hormonal involvement in the aetiology and evolution of CH.

One of the first histological studies to analyze CH in detail was performed by Sloopweg and Müller in 1986.<sup>4</sup> They established a classification of the disease based on the infiltration of islands of cartilaginous tissue and the size of the fibrocartilage layer present on the condylar head. In their study of 22 patients, they established four levels of involvement, characterizing the disease. In this classification the quantification of the islands of cartilaginous tissue was left arbitrarily to the observer due to the lack of patterns of

normality and the absence of analytical patterns of the pathological structure. Subsequent analyses by Saridin et al. confirmed complications with the classification of Sloopweg and Müller, although they did report that this classification is a useful analytical parameter.<sup>5</sup> Saridin et al.<sup>5</sup> used a methodology of histological analysis that considered only two layers for analysis due to the difficulty in recognizing each individually. However, the proposed classifications have not been related statistically to the aggressiveness of the disease or SPECT studies.<sup>4,10</sup> As a result, the dependency on the contralateral condyle for the comparison of results could be problematic (the non-hyperplastic side can also have some type of disease) and positive SPECT scan results

may not necessarily be related to the histological results.<sup>10,13</sup>

Hansson et al.<sup>14</sup> described four tissue layers in the mandibular condyle, distinguishing the connective tissue layer (layer of fibrous tissue), undifferentiated mesenchymal layer (proliferative), transitional layer, and layer of hypertrophic cartilage. This analysis is similar to that of Eslami et al.,<sup>6</sup> who reported a larger connective tissue layer in subjects with CH compared to non-hyperplastic condyles; however, Hansson et al.<sup>14</sup> found no differences between hyperplastic and healthy condyles. Saridin et al.<sup>15</sup> found a correlation between the thickness of the cartilaginous tissue layer and the number of connective tissue islands. They further indicated that young subjects had a smaller connective



**Fig. 6.** Condylar hyperplasia. (A) The articular layer was thicker and the proliferative layer showed abundant cells and scarce extracellular matrix, while the fibrocartilaginous layer showed chondrocytes with abundant extracellular matrix, some hyperplastic (haematoxylin–eosin stain; bar = 250  $\mu\text{m}$ ). (B) Type I collagen fibres were arranged in parallel to the articular surface and in multiple directions in the deepest part (picrosirius stain; bar = 100  $\mu\text{m}$ ). (C) An irregular distribution in the deepest layers with type I (red) and type III (green) collagen fibres was observed (picrosirius stain; bar = 100  $\mu\text{m}$ ). (D) Poor nucleolar reaction in all layers (AgNOR stain; bar = 20  $\mu\text{m}$ ). (For interpretation of the references to colour in this figure legend, the reader is referred to the web version of this article.)

tissue layer than older subjects. The present study showed the presence of connective tissue islands at the bone level with different levels of involvement, revealing cartilaginous tissue formation at some levels; however, quantitatively, each island presented different levels of involvement, which could indicate different levels of aggressiveness of the pathology or differences in the duration of disease activity. In most cases there was clear evidence of type I connective fibres, mainly associated with bone formation, although type III collagen was also observed.

The descriptive histological results in this study identified variations in the size and definition of the layers, types of collagenous fibre involved, presence of more or less cellularity, and reactions to alcian blue and AgNOR staining. All of the cases showed reactivity to AgNOR, demonstrating the degree of CH activity. Cases 1 and

2 presented greater reactivity, coinciding with the other histological characteristics of involvement in CH. Hence this could be used as a new biomarker to differentiate the most reactive cases, demonstrating nucleolar protein activity related to the rates of cell duplication and possible aggressiveness of the disease. This shows the variability in the histological presentation of CH, indicating that only a partial description based on staining and a description of the layers and infiltration of cartilage islands is insufficient to demonstrate the condition of the disease and may underestimate its aggressiveness. It is likely that a combination of different histological study techniques will allow the levels of aggressiveness of the disease to be defined with greater clarity and thus typify the clinical characteristics involved in its development.

In many of the studies conducted and published on CH, there has been no

clinical description of the patients, but rather a general acceptance of the presence and morphology of the pathology. Cases of osteochondroma of the mandibular condyle have been reported as aggressive growths that cause facial asymmetry,<sup>2,16</sup> and some of the published studies on CH may have included subjects with osteochondroma in their sample, which is also a type of CH.<sup>16</sup> Without a doubt this hypothesis could bring about significant changes in the assessment of the scientific literature to date, because the clinical classification of the disease requires a more precise definition to adequately influence the proposed treatment schemes.

For example, Qasem and DeYoung indicated that osteochondroma (in different anatomical areas of the body) is composed mainly of very thick cartilaginous tissue next to apparently normal trabecular bone tissue.<sup>17</sup> It does not generally present

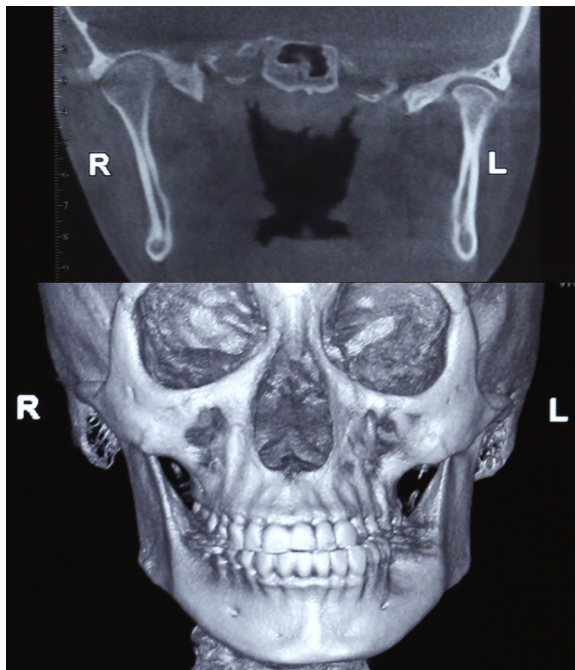


Fig. 7. Patient 5: The right mandibular condyle showing more volume than the left side. The chin point is deviated to the left side and there is a crossbite.

symptoms, and when it affects the mandibular condylar head, it is characterized clinically by the facial asymmetry it causes. Histologically it presents aspects similar to those observed in UCH<sup>2,18</sup>: cartilaginous islands are commonly seen down through the head of the condyle in CH type 2 condyles, and in CH type 1, it is uncommon to see independent cartilaginous islands extending down within the main body of the condylar head.<sup>2</sup> In addition, osteochondroma appears commonly in the second decade of life, with a predominance of CH type 2 in females (75%),<sup>16</sup> with growth medially and laterally towards the condylar tissue and a unilateral posterior open bite. Perhaps age induces changes in the cartilaginous and bone tissue,<sup>19</sup> which could associate age to the clinical presentation of this pathology. Slootweg and Müller<sup>4</sup> and Fariña et al.<sup>13</sup> reported that age may be a relevant factor in the clinical behaviour of CH. Wolford et al.<sup>2</sup> established a clinical classification in which young subjects may have UCH (characterized by crossbite and lateralization of the chin) and adult subjects may have type 2 CH (clinically with unilateral open bite), characterized as osteochondroma. Age may be one of the most important factors in these differences, considering that the alterations can be caused by changes to the normal physiology in the fibrocartilage layer of young people or adults. Thus it can be hypothesized that a factor involved in the onset of

the disease could be the same in the different types of CH, but with different behaviour due to the normal physiology in adults and young people.

The presence of cartilage islands suggests an increase in condylar height, the variation of which may be triggered by the invasion of the islands towards the interior of the bone trabeculae.<sup>20</sup> In relation to this, Meng et al. identified a significant link between active CH and the expression of bone morphogenetic protein 2 (BMP-2; associated with bone resorption), transforming growth factor  $\beta$ 1 (TGF- $\beta$ 1; proliferation and differentiation of chondrocytes), and insulin-like growth factor 1 (IGF-1; synthesis of type II collagen and phenotypic stabilization of chondrocytes).<sup>21</sup> Consequently, a clear relationship between the increased condylar size at the expense of fibrocartilage growth and condylar bone resorption was established. Meng et al. also indicated the influence of age on the physiopathology of the disease.<sup>21</sup> The present results suggest that there is a variable amount of immature connective tissue and in some areas immature bone tissue that can be observed at different levels under the fibrocartilage layer. Not all of the connective tissue islands are connected by immature tissue, so it is not possible to confirm that the presence of cartilage islands is related to the aggressiveness of CH.

Moreover, Eslami et al.<sup>6</sup> compared non-hyperplastic and hyperplastic condyles

and reported that they presented similar conditions quantitatively at the bone level. Differences were observed mainly in the amount of fibrocartilage present in the condyles. Gray et al.<sup>20</sup> also concluded that the difference between hyperplastic condyles and healthy ones lies in the amount of fibrocartilage present more than in any other histopathological condition. This is consistent with the present findings, in which this layer was abundant and with high cellularity, where AgNOR was expressed more intensely; however, Fariña et al. showed no relationship between AgNOR and UCH.

SPECT has been used as a diagnostic methodology in some investigations. In general terms, its performance in association with UCH has been positive<sup>11</sup>; however, the results of some studies have been controversial when related to the histopathological data.<sup>13</sup> Saridin et al.<sup>5</sup> indicated that histopathology cannot exclude or confirm the presence of CH. According to the authors of the present investigation, the variability can be justified in the limited description that exists in the proposed classifications, the physiopathological variations observed in each patient, and in the fact that there are no defined condylar growth patterns with the data obtained from SPECT; therefore, the increasing or decreasing activity of UCH cannot be related to SPECT results. On the other hand, the results obtained by SPECT (by comparison) are dependent on another anatomical location, usually the contralateral condyle, so if the non-hyperplastic condyle (or non-hyperplastic temporomandibular joint) presents some type of pathology, this could influence the results provided by SPECT.

In active CH there is increased connective tissue production combined with a probable initial bone resorption,<sup>21</sup> whereas the bone quality of the condylar head is characterized by wide and disorganized trabecular bone together with upper cortical perforations.<sup>22</sup> It has been reported that bone repair requires the invasion of blood vessels, which are smaller in number when the existing tissue is cartilage.<sup>23</sup> Chung et al.<sup>24</sup> also indicated that vascular endothelial growth factor (VEGF) expression is necessary for the angiogenesis and bone repair of damaged sites. Nevertheless, using a positron emission tomography (PET) analysis, Saridin et al.<sup>15</sup> reported that subjects with UCH do not show hypervascularization of the affected condyle and present no evidence of increased bone metabolism in the affected condyle. In these conditions it may be hypothesized that the condylar growth produced from



the cartilage islands and growth of the fibrocartilage layer require fewer blood vessels than required by bone tissue. Despite it being a growing tissue, there might be no increase in the regional vascularization, which could be a factor for analysis in future classifications. The present results did not assess the patients' vascular condition, but histopathological analyses with this evaluation are needed to bring new elements into this discussion.

Variations in the anatomical area of the histological sections obtained (superior or lateral aspects of the condylar head) can also have an influence, since the results of the present study showed differences in cell components, connective tissue fibres, and sizes of the layers involved in the different sectors analyzed.

Histological studies on CH tissue samples have been performed using haematoxylin-eosin and AgNOR staining analyses. The present results suggest that the incorporation of new systematic analysis techniques could lead to a better understanding of the aggressiveness and development of this pathology. Based on the present results, it appears that the published classifications analyzing the histological level may not represent the actual aggressiveness (or progression) of UCH. Objective parameters must be set that establish differences in the various levels of CH whenever variations in age and sex clearly influence the development of the pathology. New analyses of the disease are needed to classify the phenomenon not only by the clinical presentation and its treatment. These analyses could provide better information to identify the aetiology and to determine the point at which the cellular alterations occur that result in the sequence of fibrocartilage growth of the mandibular condyle.

### Funding

Dirección de Investigación UFRO DIU-FRO 14-0049.

### Competing interests

None declared.

### Ethical approval

The study was approved by the Research Ethics Committee of the Universidad de La Frontera, Temuco, Chile (0662013).

### Patient consent

Not required.

### References

- Olate S, Netto HD, Rodriguez-Chessa J, Alister JP, de Albergaria-Barbosa J, de Moraes M. Mandible condylar hyperplasia: a review of diagnosis and treatment protocol. *Int J Clin Exp Med* 2013;**6**:727-37.
- Wolford LM, Movahed R, Perez DE. A classification system for conditions causing condylar hyperplasia. *J Oral Maxillofac Surg* 2014;**72**:567-95.
- Obwegeser HL, Makek MS. Hemimandibular hyperplasia-hemimandibular elongation. *J Maxillofac Surg* 1986;**14**:183-208.
- Slootweg PJ, Müller H. Condylar hyperplasia. A clinico-pathological analysis of 22 cases. *J Maxillofac Surg* 1986;**14**:209-14.
- Saridin CP, Raijmakers PG, Slootweg PJ, Tuinzing DB, Becking AG, van der Waal I. Unilateral condylar hyperactivity: a histopathologic analysis of 47 patients. *J Oral Maxillofac Surg* 2010;**68**:47-53.
- Eslami B, Behnia H, Javadi H, Khiabani S, Shoja Saffar A. Histopathologic comparison of normal and hyperplastic condyles. *Oral Surg Oral Med Oral Pathol Oral Radiol Endod* 2003;**96**:711-7.
- Villanueva-Alcojol L, Monje F, González-García R. Hyperplasia of the mandibular condyle: clinical, histopathologic, and treatment considerations in a series of 36 patients. *J Oral Maxillofac Surg* 2011;**69**:447-55.
- Lippold C, Kruse-Losler B, Danesh G, Joos U, Meyer U. Treatment of hemimandibular hyperplasia: the biological basis of condylectomy. *Br J Oral Maxillofac Surg* 2007;**45**:353-60.
- Wurgaft R, Montenegro M. *Desarrollo y estructura de la articulación temporomandibular*. Santiago, Chile: Servimpres; 2003.
- Olate S, Almeida A, Alister JP, Navarro P, Netto HD, de Moraes M. Facial asymmetry and condylar hyperplasia: considerations for diagnosis in 27 consecutive patients. *Int J Clin Exp Med* 2013;**6**:937-41.
- Saridin C, Raijmakers P, Tuinzing DB, Becking A. Bone scintigraphy as a diagnostic method in unilateral hyperactivity of the mandibular condyles: a review and meta-analysis of the literature. *Int J Oral Maxillofac Surg* 2011;**40**:11-7.
- Raijmakers PG, Karssemakers LH, Tuinzing DB. Female predominance and effect of gender on unilateral condylar hyperplasia: a review and meta-analysis. *J Oral Maxillofac Surg* 2012;**70**:e72-6.
- Fariña R, Becar M, Plaza C, Espinoza I, Franco ME. Correlation between single photon emission computed tomography, AgNOR count, and histomorphologic features in patients with active mandibular condylar hyperplasia. *J Oral Maxillofac Surg* 2011;**69**:356-61.
- Hansson T, Oberg T, Carlsson GE, Kopp S. Thickness of the soft tissue layers and the articular disk in the temporomandibular joint. *Acta Odontol Scand* 1977;**35**:77-83.
- Saridin CP, Raijmakers PG, Kloet RW, Tuinzing DB, Becking AG, Lammertsma AA. No signs of metabolic hyperactivity in patients with unilateral condylar hyperactivity: an in vivo positron emission tomography study. *J Oral Maxillofac Surg* 2009;**67**:576-81.
- Wolford LM, Movahed R, Dhameja A, Allen WR. Low condylectomy and orthognathic surgery to treat mandibular condylar osteochondroma: a retrospective review of 37 cases. *J Oral Maxillofac Surg* 2014;**72**:1704-28.
- Qasem S, DeYoung B. Cartilage-forming tumors. *Semin Diagn Pathol* 2014;**31**:10-20.
- Roychoudhury A, Bhatt K, Yadav R, Bhutia O, Roychoudhury S. Review of osteochondroma of mandibular condyle and report of a case series. *J Oral Maxillofac Surg* 2011;**69**:2815-23.
- Yan JY, Tian FM, Wang WY, Cheng Y, Xu HF, Song HP, et al. Age dependent changes in cartilage matrix, subchondral bone mass, and estradiol levels in bone serum, in naturally occurring osteoarthritis in guinea pigs. *Int J Sci* 2014;**15**:13578-95.
- Gray RJ, Sloan P, Quayle AA, Carter DH. Histopathological and scintigraphic features of condylar hyperplasia. *Int J Oral Maxillofac Surg* 1990;**19**:65-71.
- Meng Q, Long X, Deng M, Cai H, Li J. The expressions of IGF-1, BMP-2 and TGF- $\beta$ 1 in cartilage of condylar hyperplasia. *J Oral Rehabil* 2011;**38**:34-40.
- Karssemakers LH, Nolte JW, Tuinzing DB, Langenbach GE, Raijmakers PG, Becking AG. Microcomputed tomographic analysis of human condyles in unilateral condylar hyperplasia: increased cortical porosity and trabecular bone volume fraction with reduced mineralisation. *Br J Oral Maxillofac Surg* 2014;**52**:940-4.
- Maes C. Role and regulation of vascularization processes in endochondral bones. *Calcif Tissue Int* 2013;**92**:307-23.
- Chung R, Foster BK, Xian CJ. The potential role of VEGF-induced vascularisation in the bony repair of injured growth plate cartilage. *J Endocrinol* 2014;**7**:63-75.

### Address:

Sergio Olate  
 División de Cirugía Oral y Maxilofacial  
 Universidad de La Frontera  
 Claro Solar 115  
 Oficina 414-A  
 Temuco  
 Chile  
 Tel: +56 45 2325000;  
 Q2Fax: +56 45 2325001  
 E-mail: sergio.olate@ufrontera.cl